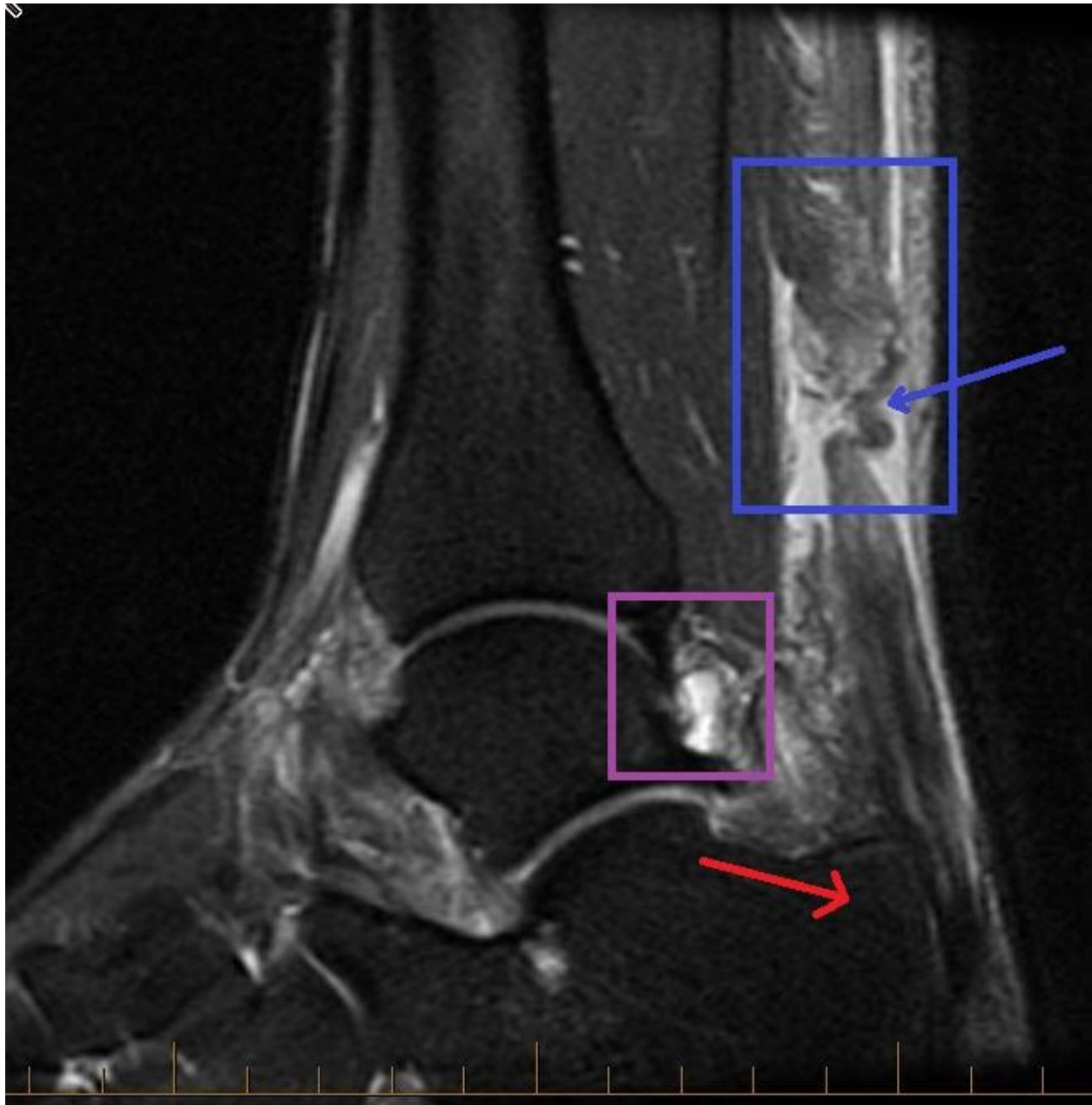


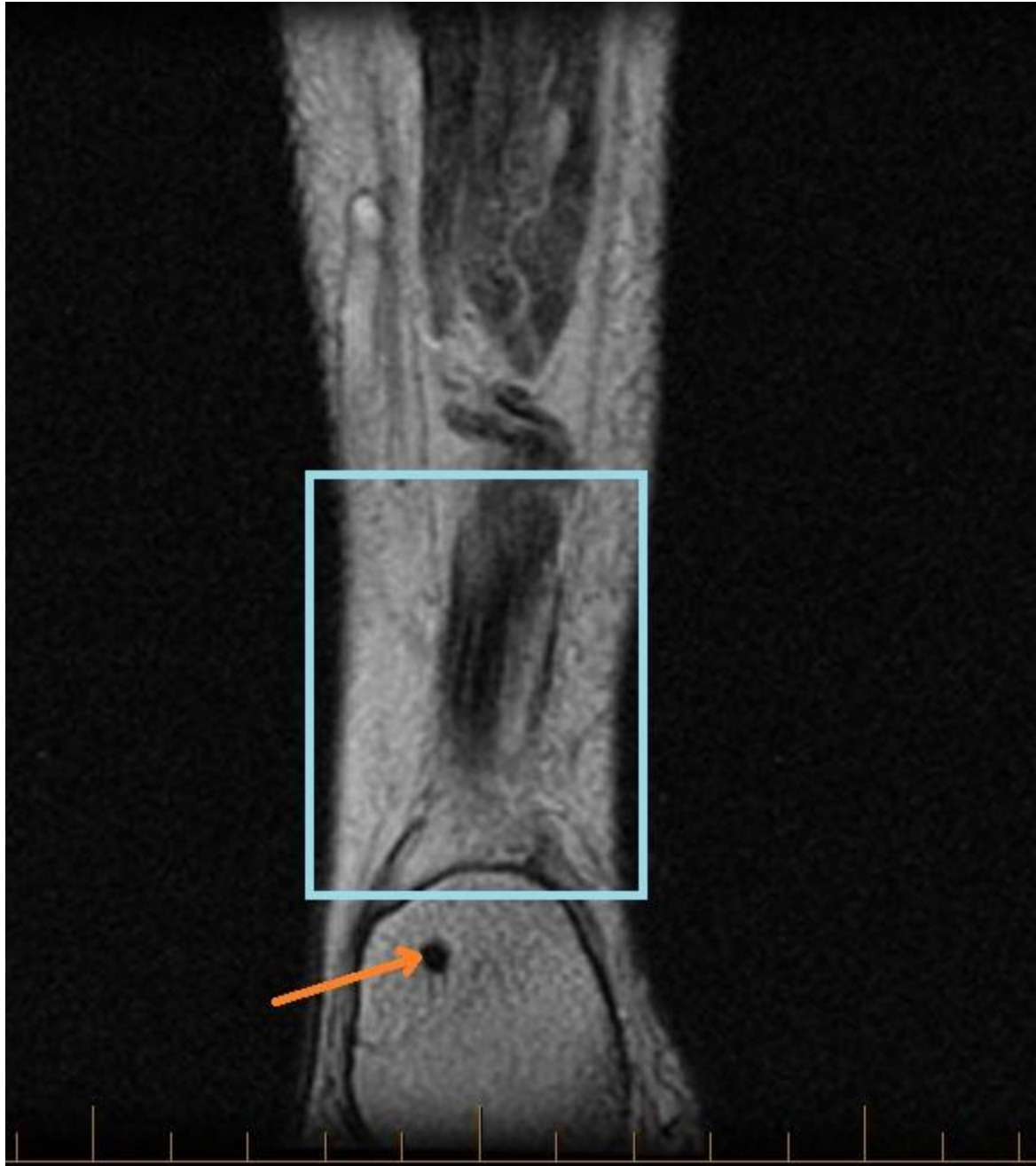'Heel' This Legendary Injury That Took Down a NFL Player

Patient was running then hears a pop sound and finally presents with posterior ankle pain. *Note: long- and short-axis fat- and water-weighted images performed and shown below.*



*Lateral view in sagittal plane*

Acute rupture of largest, strongest and thickest tendon in the human body – The Achilles. This rupture occurred 5.8 cm above (blue arrow/box in above graphic) the calcaneus (red arrow) with remaining chronically hypertrophic plantar fascia. A 1 to 2 cm diastasis (3 to 6 cm usually a complete rupture) with normal appearance in torn edges. Also, there appears to be a cyst prolapsing dorsolaterally (purple box).



*Posterior view in coronal plane*

But wait! It's not all Greek here. Medial and anterior tendons intact while lateral abnormal due to 3 cm split tear (light blue box in above graphic) peroneus brevis splits retro- and inframalleolar that appears chronic. No high-grade arthrosis in articular surfaces. Also, calcaneal exostectomy (orange arrow in above graphic) has smooth appearance.

Copyright © Michael Siebenaler